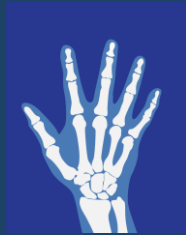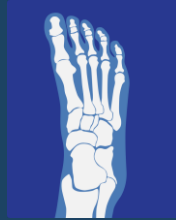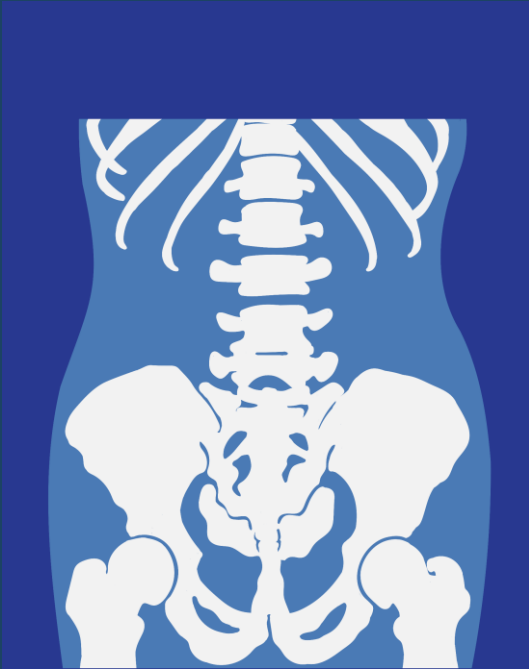


# Psoriatic Arthritis



RHEUMATOLOGY.PHYSIO  
**ONLINE.**



# Psoriatic Arthritis



Recognition

Extra-Articular features

Decision making aids

Investigation

Onwards referral

# Spondyloarthritis



## AxSpA

Ankylosing Spondylitis

r-AxSpA

nr-AxSpA

Enteropathic

Psoriatic

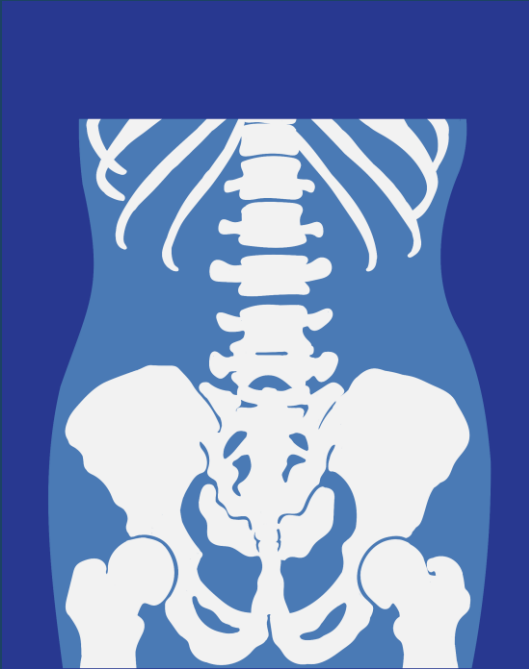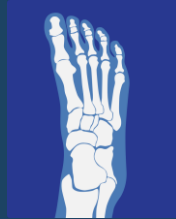
## PSpA

Psoriatic

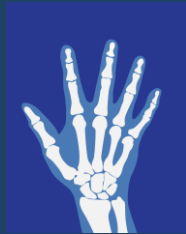Enteropathic

Peripheral Enteseopathy

# Psoriatic Arthritis



Inflammatory joint disease associated with Psoriasis (Ps)  
Prevalence in Ps population is c. 30%



A proportion will have arthropathy symptoms prior to skin involvement... (15-20%)

# Extra Articular Features



Current, history or family history Psoriasis

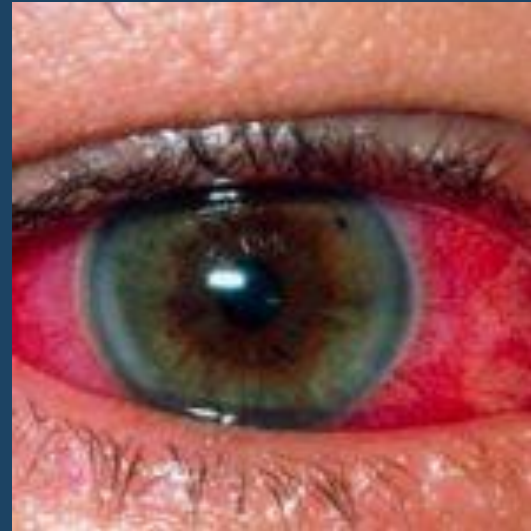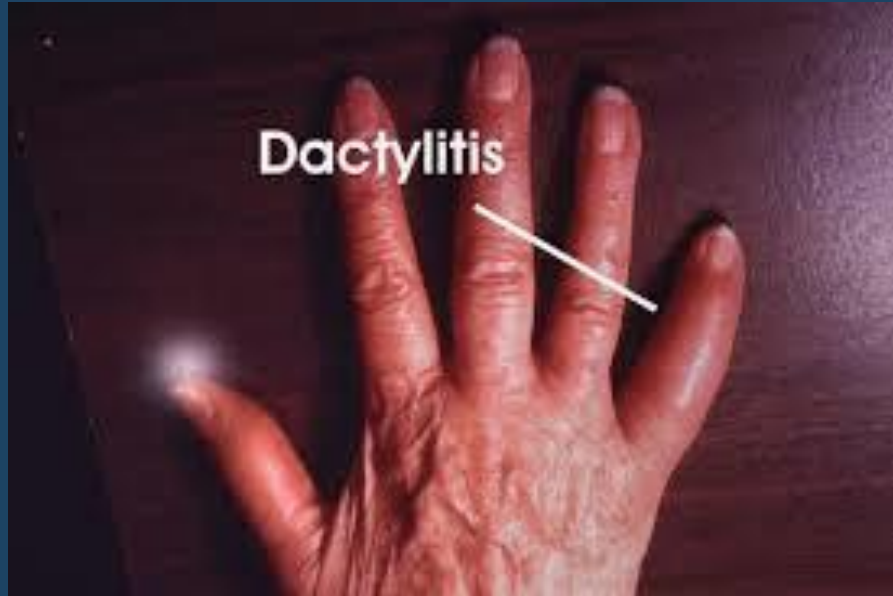Nail pitting

Dactylitis

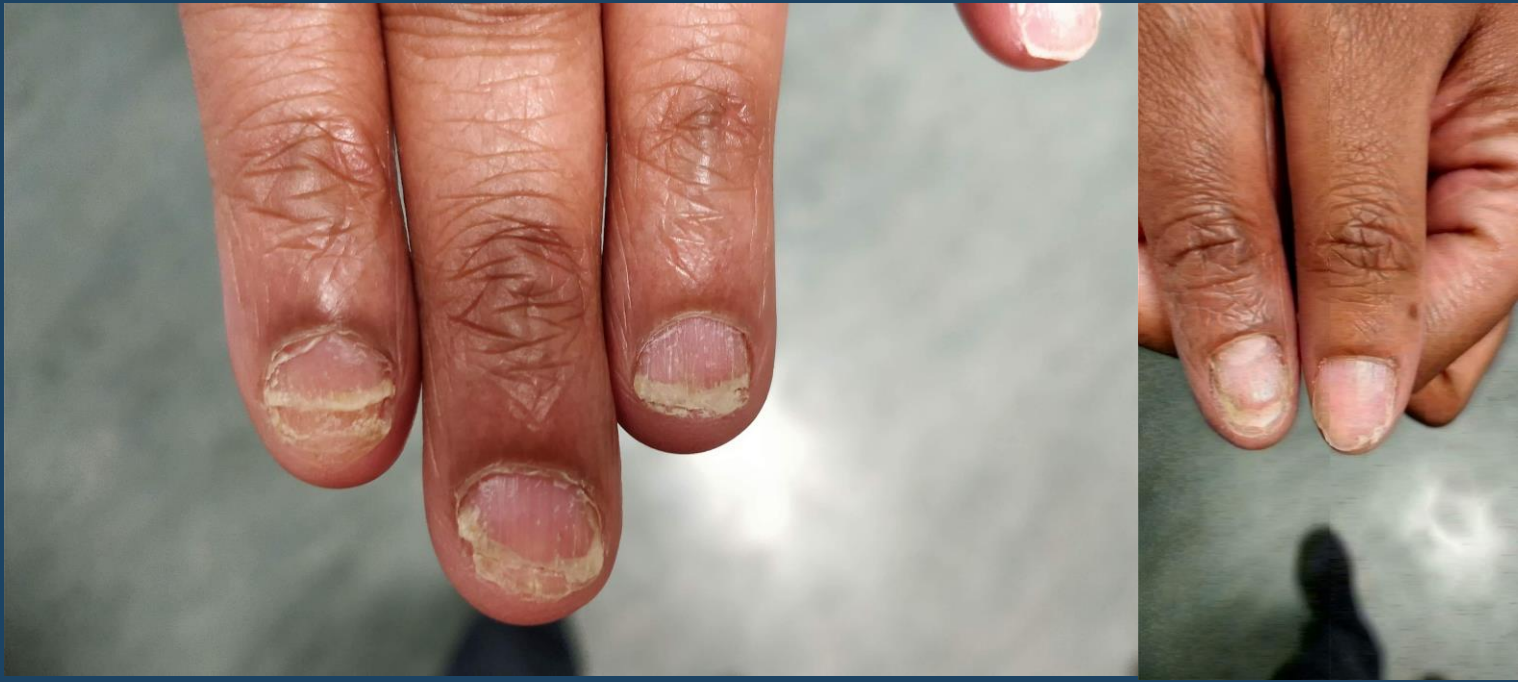Inflammatory back pain

Enthesitis

# Extra Articular Features



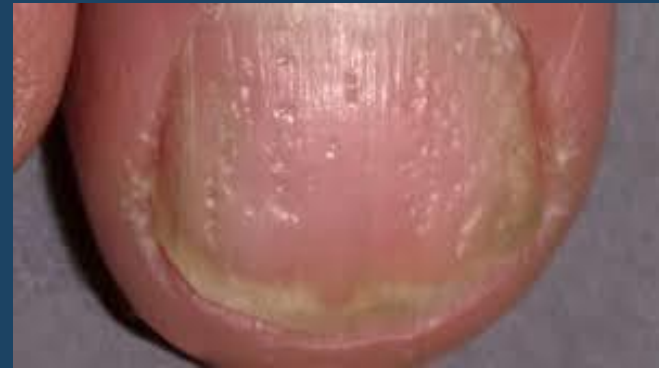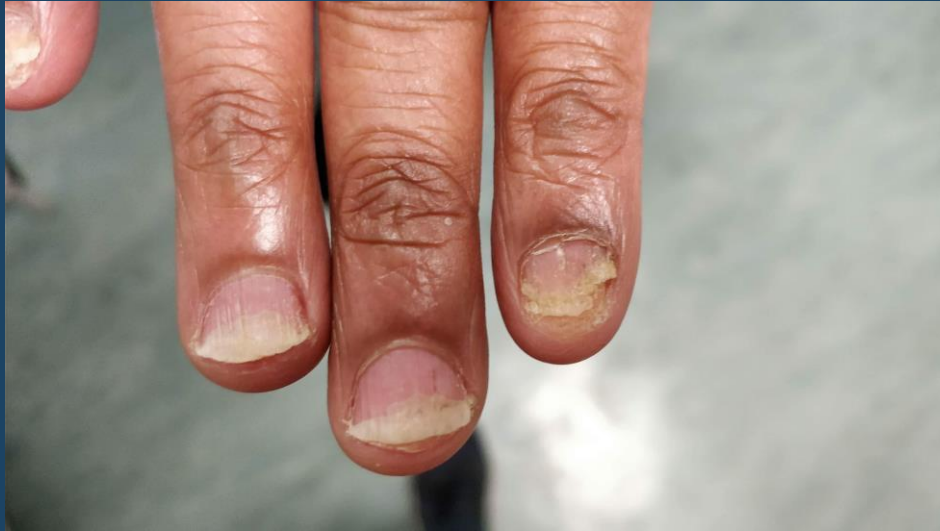# Nails



# Nails



RHEUMATOLOGY.PHYSIO  
ONLINE.





# SCREEND'EM BEFORE YOU TREAT'EM

A clinical tool to help identify spondyloarthritis (SpA) in patients with tendinopathy.

## SKIN

6-42% of patients with psoriasis develop psoriatic arthritis.



## COLITIS OR CHROHN'S



Arthritis is one of the most common extra-intestinal manifestations of inflammatory bowel disease. The prevalence of SpA in patients with Crohn's is estimated to be 26% at 6 year follow up.

## RELATIVES

There is a strong relationship between SpA and HLA-B27 positive patients.

Family members of patients with SpA who are HLA-B27 positive have a 16-fold increase chance of developing ankylosing spondylitis if they are also HLA-B27 positive.



## EYES



Acute anterior uveitis (AAU) can cause a painful, red eye with photophobia and blurred vision. 40% of patients presenting with idiopathic AAU have undiagnosed SpA. 50% of patients with AAU are HLA-B27 positive and >50% of these have SpA.

## EARLY MORNING STIFFNESS

Inactivity related stiffness that lasts for more than 30 minutes is suggestive of inflammatory disease.

## NAILS

Nail lesions occur in 87% of SpA patients and include:



- small depressions in the nail (pitting)
- thickening of the nails
- painless detachment from the nail bed (onycholysis).

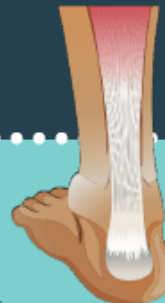## DACTYLITIS

Sausage like swelling of the digits is a hallmark sign of psoriatic arthritis, occurring in 50% of cases.



## ENTHESITIS

98% of SpA patients have at least one abnormal enthesis. The most common sites are the Achilles tendon, plantar fascia and patellar tendon.



## MOVEMENT & MEDICATION EFFECT

SpA patients report improvement with activity but not with rest, and a favourable response to NSAIDs.

Created by  
Paul Kirwan

 @pdkirwan

ISBN/EAN: 978-90-75823-92-9, d18 page 32

 THE KNEE RESOURCE  
REHABILITATION  
designed by  freepik.com



RHEUMATOLOGY.PHYSIO  
ONLINE.

In your patient with chronic back pain, tick all the symptoms that apply to determine the likelihood of axial spondyloarthritis

Inflammatory type of back pain

Heel pain (enthesitis)

Peripheral arthritis

Dactylitis

Iritis or anterior uveitis

Psoriasis

IBD (Crohn's disease or ulcerative colitis)

Positive family history of axial SpA, reactive arthritis, psoriasis, IBD or anterior uveitis

Good response to NSAIDs

Positive family history of axial SpA, reactive arthritis, psoriasis, IBD or anterior uveitis

Good response to NSAIDs

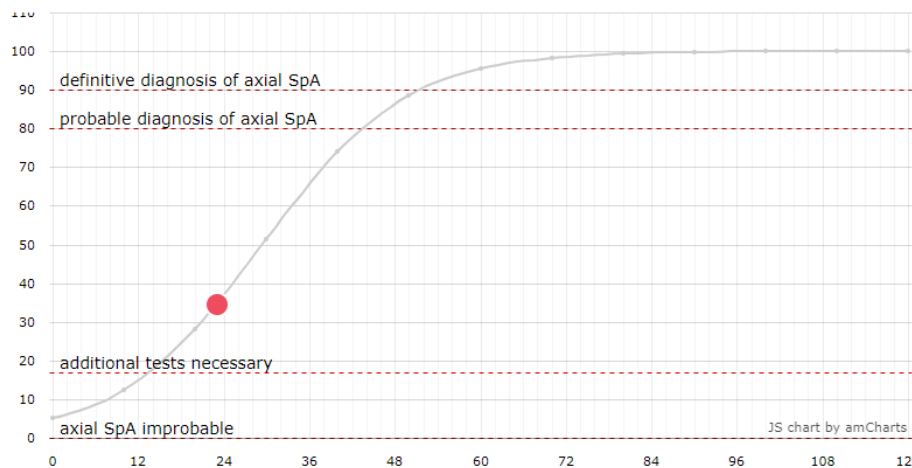
Raised acute-phase reactants (CRP/ESR)

HLAB27

Sacroiliitis shown by MRI

[SHOW RESULTS](#)

## Sacroiliitis shown by MRI

[SHOW RESULTS](#)

### Additional tests necessary

This patient may have Axial SpA but further tests are necessary – assessment by a rheumatologist is recommended

If you would like to let us know the outcome of the diagnosis, please do this via the [Contact](#) page.



RESEARCH



DIAGNOSIS



IBP



ASAS AxSpA

# What to do?



## Priority 1 – RHEUMATOLOGY

Bloods – ESR, CRP, RF\*, (HLA-B27\*\*)

MRI/ultrasound

Anti-Inflammatories?

\* -ve 87%

Dermatology?

\*\* 50-60%

## Case Study



## Manual Therapies



## Graded Programs



# Psoriatic Arthritis



RHEUMATOLOGY.PHYSIO  
**ONLINE.**

